



PATIENT

Velcro Footit

SPECIES

Canine

BREED

Ladradoodle

SEX

Male Neutered

AGE

10 years

WEIGHT

81.2lbs

INTERPRETED BY

Maggie Machen
Lamy, DVM
DACVIM (Cardiology)

IMAGING PERFORMED BY

Pamela Harrigan,
RDCS

HOSPITAL NAME

Mass Veterinary Services

REFERRING VET

Dr. Masloski

INVOICE

30534

DATE

5/2/23

PRESENTING CLINICAL SIGNS

History: Velcro was noted to have a heart murmur in February and potentially longer. He is in need of surgery for a mass removal. He is presently doing well with a good appetite and normal activity level. On exam: NSR, grade II/VI murmur with PMI left apical area, PSS, lung fields clear, mm pink, moist, CRT < 2. BP: 190mmHg x 5 (stressed). Current medications: 1) glucosamine 2) herbal stress meds---given last night and this morning *Sedated with Propofol for study*.

ECHOCARDIOGRAM FINDINGS

2D, m-mode, color flow and Doppler imaging is available.

Left ventricle: The LV diameter is normal with adequate myocardial function. LV wall thicknesses are normal.

Left atrium: The left atrium is normal.

Mitral valve: The mitral valve is mildly thickened with no prolapse into the left atrial lumen. Mild anterior-directed mitral regurgitation with a normal velocity.

Aortic valve/aorta: The aortic valve is normal in morphology and mobility. Normal aortic outflow velocity; laminar flow. No aortic insufficiency.

Right ventricle: Normal right ventricular diameter and morphology indicating no overt evidence of pulmonary arterial hypertension.

Right atrium: Normal RA dimension.

Tricuspid valve: The tricuspid valve appears normal with trace tricuspid regurgitation; normal velocity.

Pulmonic valve/pulmonary artery: The pulmonic valve is normal in morphology and mobility. No pulmonic insufficiency. Normal RVOT velocity; laminar flow.

Pericardium/other: No pericardial or pleural effusion noted. No obvious cardiac masses.

Heart rhythm: ECG reveals a sinus rhythm with an average HR of 110bpm.

2-Dimensional Measurements

| | |
|--------------------|-----|
| Ao diam (cm) | 2.7 |
| LA diam (cm) | 2.8 |
| LA:Ao (Swe) | 1.1 |
| IVS thickness (cm) | 1.2 |
| LVID diastole (cm) | 3.9 |
| PW thickness (cm) | 1.2 |
| LVID systole (cm) | 2.8 |
| FS (%) | 28 |

Doppler Measurements

| | |
|----------------|-----|
| PV Vmax (m/s) | 0.5 |
| AoV Vmax (m/s) | 1.1 |
| MR Vmax (m/s) | 5.1 |
| TR Vmax (m/s) | 2.0 |
| TR PG (mmHg) | 16 |

INTERPRETATION OF THE FINDINGS

The cause of the murmur is chronic degenerative valve disease causing mild mitral and trace tricuspid regurgitation. Lack of significant left atrial enlargement indicates the current risk for complication is low. No concurrent issues such as pulmonary hypertension are noted in this study.

Assessment of progression in the future will help predict long term prognosis, which is highly variable at this stage (B1).

The reported blood pressure is elevated and should be reassessed for accuracy particularly given no reported clinical signs of severe hypertension (retinal changes, etc.) or evidence of LVH on echo. Ideally obtain serial measurements in a controlled, low stress environment and continue until 3 consecutive readings plateau within 5mmHg of variability. If persistently >180mmHg despite a relatively calm demeanor, recommend institution of amlodipine to effect. Additionally, if deemed accurate, screening for



PATIENT
Velcro Footit

predisposing underlying causes of SHT is recommended (Cushing's, PLN, adrenal tumor, etc.), as primary disease is relatively uncommon and a rule out diagnosis.

SPECIES
Canine

BREED
Ladradoodle

SEX
Male Neutered

AGE
10 years

WEIGHT
81.2lbs

RECOMMENDATIONS

- In an asymptomatic dog without significant left atrial enlargement, no cardiac medications are clearly indicated.
- Reassess BP as discussed.
- Omega fatty acid supplementation and mild salt restriction may be of some long-term benefit.
- Anesthetic risk is considered mild if needed. Cardiac protective drug choices (opioid/benzodiazepine premedication, propofol or alfaxalone induction, isoflurane gas) are recommended. Pre-oxygenate for 5-10 minutes prior to induction. Monitor for arrhythmias, hypotension, and hypoxia both intra and post-operatively and intervene as necessary. Mild IV fluid restriction is recommended to avoid fluid overload. Avoid heart rate stimulating drugs such as atropine unless clinically indicated.
- Monitor for development of a cough, labored breathing, exercise intolerance or collapse episodes.

PLAN

- Recommend conservative monitoring with a recheck echocardiogram in 6-12 months, sooner if any development of clinical signs.

INTERPRETED BY

Maggie Machen Lamy, DVM
DACVIM (Cardiology)

IMAGING PERFORMED BY

Pamela Harrigan, RDCS

HOSPITAL NAME

Mass Veterinary Services

REFERRING VET

Dr. Masloski

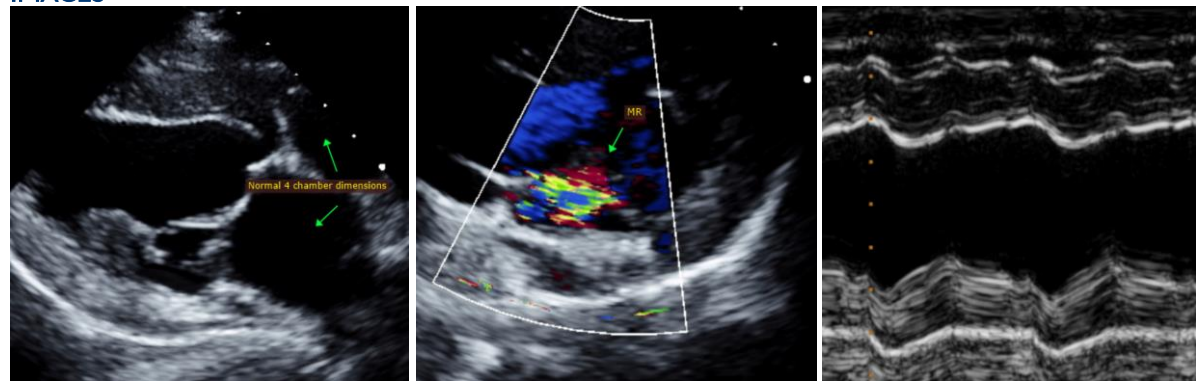
INVOICE

30534

DATE

5/2/23

IMAGES



The information and recommendations provided are based on the images presented by the referring veterinarian. No evaluation can be communicated regarding pathology that was not visible in the image/video clips provided.

Thank you for this referral. This report was generated using transcription software, and minor dictation errors may be present. If the clinical or image interpretation does not parallel your findings or if I can be of any further assistance, please contact me.

Maggie Machen Lamy, DVM
Diplomate of the American College of Veterinary Internal Medicine (Cardiology)
info@sonopath.com

Echocardiogram performed by:

Pamela Harrigan, RDCS
Pet Animal Ultrasound Service (4paus.com)